

Cataract Surgery Evaluation of a Sjögren's Patient

Esen Akpek, MD

INITIAL PRESENTATION

A 63-year-old female patient with Sjögren's-related dry eye presented for cataract surgery evaluation.

The patient was on topical cyclosporine drops and over the counter preserved artificial tears for several years prior to presentation.

EXAM

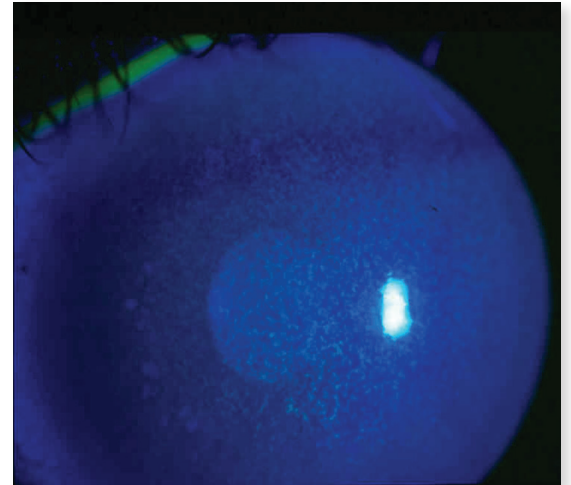
Slit-lamp examination demonstrated significant corneal punctate erosions highlighted with topical fluorescein. Unanesthetized Schirmer's test results were 3 and 4 mm in the right and left eye respectively.

TREATMENT PLAN

The patient was advised to switch to preservative free artificial tears, continue with the topical cyclosporine drops and increase the dose to four times daily from twice daily. In addition, inferior permanent tear duct plugs were inserted and autologous serum tears at 50% concentration four times daily were added to the regimen.

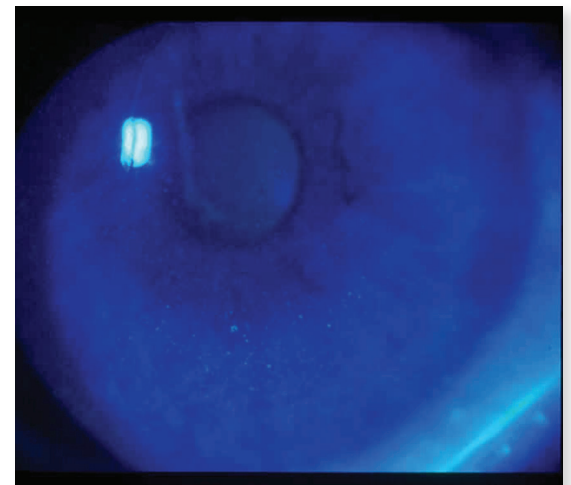
FOLLOW UP

Eight weeks into the new treatment using autologous serum tears, slit-lamp appearance of the corneal fluorescein staining demonstrated significant improvement.



EXAM

significant corneal punctate erosions highlighted with topical fluorescein



FOLLOW UP

corneal fluorescein staining demonstrated significant improvement